


## ORIGINAL ARTICLES



Dr. McNamara

### *A method of cephalometric evaluation*

**James A. McNamara, Jr., D.D.S., Ph.D.\***

*Ann Arbor, Mich.*

This paper describes a method of cephalometric analysis which is currently used by the author in the evaluation and treatment planning of orthodontic and orthognathic surgery patients. In the analysis of a single film, the positions of the maxilla and mandible are related to cranial structures and to each other. Criteria for evaluation of the anteroposterior and vertical positions of the upper and lower incisors are provided, as is the documentation of the standards for each of the measures. In addition, the analysis of serial films is considered and a step-by-step outline of the cephalometric procedure is presented.

**Key words:** Cephalometrics, analysis, maxilla, mandible, incisors

The purpose of this article is to describe a method of cephalometric analysis which I am currently using in the evaluation and treatment planning of orthodontic and orthognathic surgery patients. As is true of any cephalometric analysis, the method described here is only one of many diagnostic tools used to determine the type and focus of therapy for an individual patient. In addition to describing the method of analysis, I shall present certain cephalometric standards against which the values of a given patient can be compared.

Since the introduction of cephalometrics by Broadbent<sup>1</sup> in 1931, a number of different analyses have been devised. Those of Downs,<sup>2-4</sup> Steiner,<sup>5-7</sup> Tweed,<sup>8, 9</sup> and Ricketts<sup>10-12</sup> probably have gained the widest acceptance. The "Wits" appraisal<sup>13, 14</sup> and the analy-

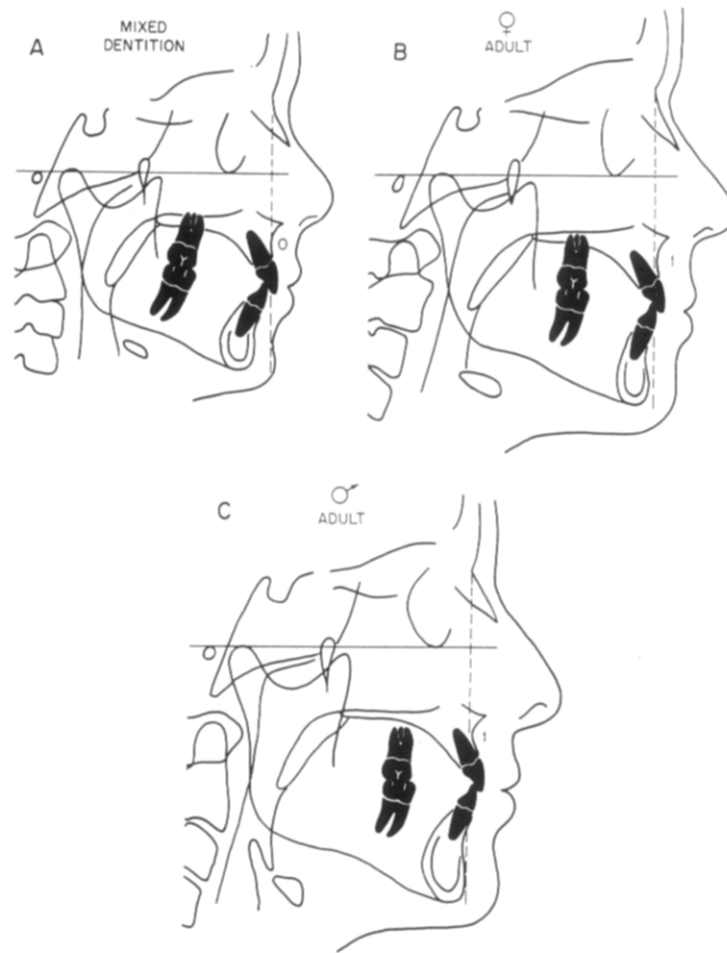
ses of Jarabak,<sup>15</sup> Coben,<sup>16</sup> Wylie,<sup>17, 18</sup> Sassouni,<sup>19, 20</sup> Enlow and associates,<sup>21</sup> and Bimler<sup>22</sup> perhaps are less widely used, but they are nevertheless well known.

Why another cephalometric analysis? Most of the analyses available today were conceived during the period (1940 to 1970) when significant alterations in craniofacial structural relationships were thought impossible. During the last 10 years, however, clinical orthodontics has seen the advent of numerous orthognathic surgery procedures which allow three-dimensional repositioning of almost every bony structure in the facial region and of functional appliance therapy which presents new possibilities in the treatment of skeletal discrepancies. Therefore, a need has arisen for a method of cephalometric analysis that is sensitive not only to the position of the teeth within a given bone but also to the relationship of the jaw elements and cranial base structures one to another. In short, the method of analysis described here represents an effort to relate teeth to teeth, teeth to jaws, each jaw to the other, and the jaws to the cranial base.

Cephalometrics is not an exact science. Even

This research was supported in part by United States Public Health Service Grant 03610.

\*Professor of Anatomy and Cell Biology, Professor of Dentistry (Orthodontics), and Research Scientist, Center for Human Growth and Development, The University of Michigan.



**Fig. 1.** The relationship of the nasion perpendicular to the maxilla at point A. **A**, Ideal mixed dentition (small face). **B**, Ideal adult female (medium face). **C**, Ideal adult male (large face).

though head films can be measured with precision, the measurement error can vary greatly with any given landmark.<sup>23</sup> Thus, the analysis method described in this article is presented as a *language*. This language can be used by the clinician to communicate to other clinicians and, perhaps more important, to themselves the identification and description of a set of structural relationships that are critical to the diagnosis and treatment planning of a given case. In addition, the basic principles of this analysis are easily communicated to lay persons, such as patients and parents, and to other dental professionals who do not have detailed knowledge of cephalometrics. One does not have to have in-depth experience in cephalometric measurement to understand the general relationships being discussed.

The analysis method is derived, in part, from the principles of the cephalometric analyses of Ricketts<sup>10-12</sup> and of Harvold,<sup>24, 25</sup> although other aspects, such as the construction of the nasion perpendicular and the point A vertical, are presumed to be original.

This method of cephalometric analysis is conventional in nature in that it consists of a predetermined set of measurements of angles and distances applied to each cephalometric tracing. This analysis method is useful in the diagnosis and treatment planning of the individual patient when the values derived from the tracing of the patient's initial head film are compared to established norms. Therefore, composite normative standards based on three cephalometric samples are provided throughout the text. The first sample contains normative data derived from lateral cephalograms of the children comprising the Bolton standards,<sup>26</sup> the longitudinal records of whom were retraced and digitized by Behrents and McNamara<sup>27</sup> to include all the landmarks necessary for the present analysis. The second sample contains selected values from a group of normal children from the Burlington Orthodontic Research Centre who also were followed longitudinally. The third group considered is the Ann Arbor sample of 111 young adults who, in the opinion of my co-workers

and myself,<sup>28</sup> have good to excellent facial configurations. Patients in this latter group had a Class I occlusion and good skeletal balance with an orthognathic facial profile. The average age of the females in the sample was 26 years 8 months, while the average age of the males was 30 years 9 months at the time the cephalogram was taken. Whenever possible, all cephalometric measures from all these samples have an 8% enlargement factor included.

The composite normative standards presented in the text were determined by arbitrarily combining comparable average values of the Burlington, Bolton, and Ann Arbor samples. These values have been empirically tested and redefined for the past 9 years and have been found useful in determining treatment protocols. Retrospectively, these protocols appear to have been appropriate.

A part of the analysis by which serial radiographs are evaluated can be used to estimate increments of growth and subsequent effects of treatment and incorporates the four-part superimposition scheme of Ricketts.<sup>10-11</sup> However, this method of cephalometric analysis only by coincidence may provide an optimal evaluation of serial changes. Bookstein<sup>29-33</sup> has demonstrated the limitations of conventional cephalometric approaches which dictate the use of a specific set of measures. The tensor approach developed by Bookstein involves the construction of measures only after an analysis of shape change has been made. In other words, the nature of the change determines the measures to be used to evaluate it. Empirically, the measurements used in the analysis method presented in this article seem to yield useful clinical information. However, an analysis such as that involving the tensor method of Bookstein may be used to determine what information the analysis presented here may be omitting.

**ANALYSIS OF A SINGLE FILM**

The analysis of a single lateral cephalogram will be presented in this section.

**Relating the maxilla to the cranial base**

In an evaluation of the position of the maxilla relative to the cranial base, two factors are considered. The first is the skeletal relationship of point A to the nasion perpendicular, and the second is the patient's soft-tissue profile.

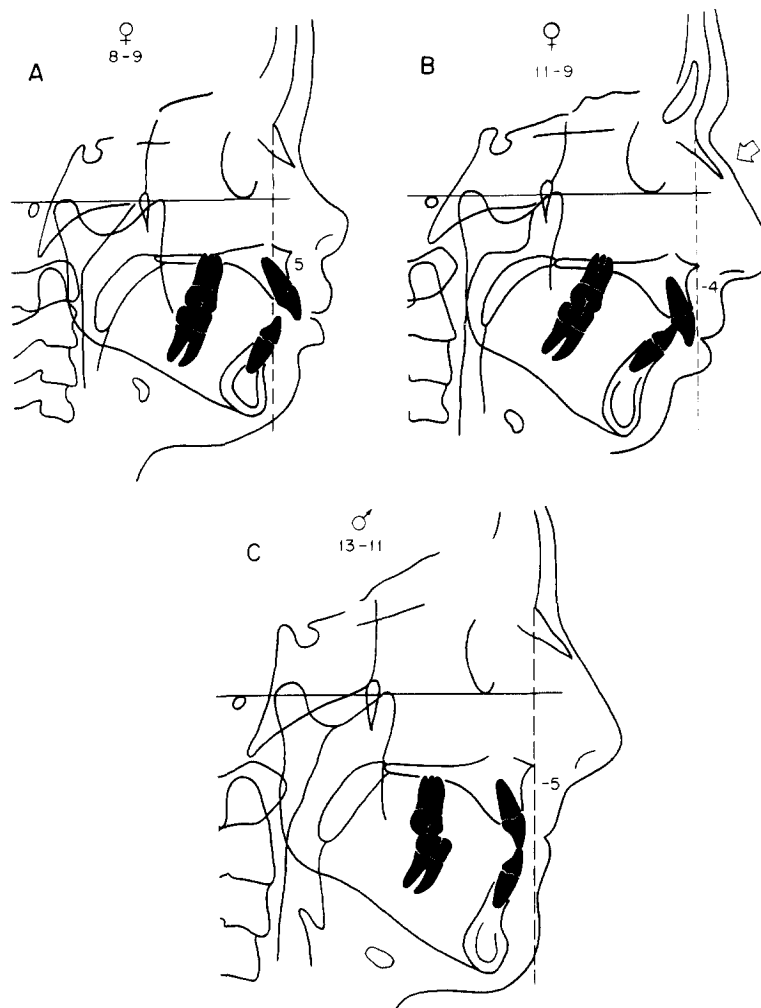
The construction of the nasion perpendicular is accomplished by first defining the Frankfort horizontal plane (Fig. 1), using anatomic porion (the superior aspect of the external auditory meatus) and orbitale (the lower border of the orbit of the eye) as reference points.

**Table I.** Cephalometric values of 111 untreated adults with well-balanced faces and good occlusions (Ann Arbor sample, 1984)

	Female (n = 73)		Male (n = 38)	
	$\bar{X}$	SD	$\bar{X}$	SD
<b>Maxilla to cranial base</b>				
Nasion perpendicular to point A (mm)	0.4	2.3	1.1	2.7
SNA angle	82.4°	3.0°	83.9°	3.2°
<b>Mandible to maxilla</b>				
Effective mandibular length (mm) (condyion to gnathion)	120.2	5.3	134.3	6.8
Effective midfacial length (mm) (condyion to point A)	91.0	4.3	99.8	6.0
Maxillomandibular differential (mm)	29.2	3.3	34.5	4.0
Lower anterior facial height (mm) (ANS to menton)	66.7	4.1	74.6	5.0
Mandibular plane angle	22.7°	4.3°	21.3°	3.9°
Facial axis angle	0.2°	3.2°	0.5°	3.5°
<b>Mandible to cranial base</b>				
Pogonion to nasion perpendicular (mm)	-1.8	4.5	-0.3	3.8
<b>Dentition</b>				
Upper incisor to point A vertical (mm)	5.4	1.7	5.3	2.0
Lower incisor to A-Po line (mm)	2.7	1.7	2.3	2.1
<b>Airway</b>				
Upper pharynx (mm)	17.4	3.4	17.4	4.3
Lower pharynx (mm)	11.3	3.3	13.5	4.3

**Table II.** Composite norms

	Mixed dentition	Change per year	Adult
<b>Maxillary skeletal</b>			
Nasion perpendicular to point A (mm)	0	Minimal	1
<b>Maxillary dental</b>			
Upper incisor to point A vertical (mm)	4-6	No change	4-6
<b>Mandibular dental</b>			
Lower incisor to A-Po line (mm)	1-3	No change	1-3
<b>Mandibular skeletal</b>			
Pogonion to nasion perpendicular (mm)	-8 to -6	0.5	-2 to +4
<b>Vertical measures</b>			
Mandibular plane angle	25°	-1 every 3-4 years	22°
Facial axis angle	0° (90°)	No change	0° (90°)



**Fig. 2.** **A**, Maxillary skeletal protrusion, as indicated by the 5 mm distance from point A to the nasion perpendicular. **B**, Maxillary skeletal retrusion. The arrow indicates a bump (dorsal hump) on the external contour of the nose. This patient has a steep mandibular plane angle and mandibular skeletal retrusion as well. The nasolabial angle is within normal limits. **C**, Maxillary skeletal retrusion and an obtuse nasolabial angle.

As Ricketts<sup>10-12</sup> has advocated for many years, anatomic porion, not machine porion, should be used in the determination of the Frankfort horizontal plane. Machine porion, as determined by the ear rods of the cephalometric head holder, can be as much as 1 cm away from the actual position of anatomic porion. A similar radiolucency, the *internal* auditory meatus, is distinguished by being smaller and is located posterior and superior to the external auditory meatus.

After porion and orbitale have been identified, the Frankfort horizontal is drawn. A vertical line (the *nasion perpendicular*) is constructed perpendicular to the Frankfort horizontal and extended inferiorly from na-

sion. The first measurement to be made is the linear distance from point A to the nasion perpendicular.

In the Ann Arbor sample of adults with well-balanced faces, point A is in front of the nasion perpendicular by 0.4 mm in females and 1.1 mm in males (Table I). In our composite norm for adults of both sexes point A is 1 mm ahead of the nasion perpendicular (Table II).

Data derived from the Bolton standards<sup>27</sup> indicate that the SNA angle increases minimally with age (approximately 1° from ages 6 to 18). Since a 1° change at point A is equivalent to a 1 mm linear change in the position of point A relative to nasion, one can extrapo-

**Table III.** Skeletal values derived from the Bolton standards (N = 16 for each sex at each age, standardized 8% enlargement)

	6 years		9 years		12 years		14 years		16 years		18 years	
	$\bar{X}$	SD	$\bar{X}$	SD	$\bar{X}$	SD	$\bar{X}$	SD	$\bar{X}$	SD	$\bar{X}$	SD
<i>Female</i>												
Mandibular length (Co-Gn)	97.7	3.4	106.1	3.4	113.1	3.6	118.9	5.0	120.0	3.4	121.6	4.5
Midfacial length (Co-point A)	79.8	2.2	85.0	2.3	89.6	2.4	92.1	2.7	92.7	2.3	93.6	3.2
Maxillomandibular differential	17.9	8.1	21.0	2.7	23.4	3.0	26.7	4.1	27.3	3.0	28.0	3.2
Lower anterior facial height	57.9	3.7	60.0	2.9	62.6	4.5	65.6	4.9	66.1	4.3	67.2	4.7
<i>Male</i>												
Mandibular length (Co-Gn)	99.3	3.6	107.7	3.8	114.4	4.3	120.6	4.3	126.8	4.7	131.0	4.6
Midfacial length (Co-point A)	81.7	3.4	87.7	4.1	92.1	4.1	95.2	3.2	98.9	4.4	100.9	3.9
Maxillomandibular differential	17.5	2.2	20.0	2.6	22.2	3.1	25.3	3.5	27.9	3.3	30.0	3.9
Lower anterior facial height	58.4	3.1	61.1	3.6	64.3	3.6	66.8	3.9	69.7	4.3	71.6	4.9

late the position of point A relative to the nasion perpendicular during the mixed dentition. Thus, the composite norm for the relationship of point A to the nasion perpendicular is 0 mm in the mixed-dentition person (Fig. 1, A) and 1 mm in the adult female (Fig. 1, B) and the adult male (Fig. 1, C).

Usually the separate evaluations of the hard and soft tissues lead to the same diagnostic conclusions. A patient with maxillary prognathism or maxillary dentoalveolar protrusion routinely displays an acute nasolabial angle, while a patient with maxillary retrusion often has an obtuse nasolabial angle. However, sometimes a discrepancy exists between the clinical and cephalometric observations. For example, this could be due to an excessive thinness or thickness of the overlying soft tissue. In these cases, it is advisable to use the soft-tissue profile as the *primary* guide. Scheideman and co-workers<sup>34</sup> report that the nasolabial angle was approximately 110° in their sample of dentofacial normals.

Fig. 2, A presents an example of a patient with the clinical appearance of maxillary prognathism and a relatively acute nasolabial angle. The maxilla at point A lies 5 mm ahead of the nasion perpendicular.

The cephalometric evaluation in Fig. 2, B indicates that this person has a retrusive maxilla and a retrusive mandible. This type of patient is often characterized clinically as having a steep mandibular plane angle, a convex facial profile, an obtuse nasolabial angle, and a

dorsal hump or convex superior nasal ridge (see arrow in Fig. 2, B). Clinically, the appearance of the patient's large nose is exaggerated by the retrusive position of both upper and lower jaws. In spite of the retrusive position of the maxilla shown in Fig. 2, B, the nasolabial angle of this person is within normal limits.

A retrusive maxilla occurs more frequently than is usually recognized, even in Class II malocclusions. In a study of 277 Class II persons,<sup>35</sup> there were more cases of maxillary skeletal retrusion than of skeletal protrusion. This finding was observed regardless of whether the SNA angle or the relationship of point A to the nasion perpendicular was used to evaluate maxillary position.

In contrast to the person depicted in Fig. 2, B, the person depicted in Fig. 2, C has a retrusive maxilla, a Class III molar relationship, and an obtuse nasolabial angle. In this case, the length of the mandible should be estimated following a theoretical correction of position of point A relative to the nasion perpendicular.

The nasion perpendicular is usually, but not always, a reliable line of orientation for determining maxillary position. One exception is the Class III malocclusion in which a short anterior cranial base exists (see Fig. 9, B later in text). In that instance, the backward position of nasion (which can be evaluated clinically by examining the soft-tissue profile) results in the construction of an erroneous nasion perpendicular, thereby giving the appearance that the maxilla and

**Table IV.** Values derived from the Burlington Orthodontic Research Centre (standardized 8% enlargement)

	6 years		9 years		12 years		14 years		16 years		18 years		20 years	
	$\bar{X}$	SD	$\bar{X}$	SD	$\bar{X}$	SD	$\bar{X}$	SD	$\bar{X}$	SD	$\bar{X}$	SD	$\bar{X}$	SD
<i>Female</i>	(N = 56)		(N = 57)		(N = 56)		(N = 48)		(N = 54)		(N = 22)		(N = 44)	
Mandibular length (Co-Gn)	94.1	3.3	103.3	5.3	110.2	6.4	114.9	7.1	117.7	4.5	118.9	4.7	116.8	7.3
Midfacial length (Co-point A)	78.6	3.1	88.3	4.0	87.3	4.6	89.2	5.2	90.9	4.1	91.1	3.1	90.7	5.2
Maxillomandibular differential	15.5	—	15.0	—	22.9	—	25.7	—	26.8	—	27.8	—	26.1	—
Lower anterior facial height	57.2	3.4	61.2	3.9	63.4	4.7	66.2	5.1	66.6	4.7	68.5	4.7	66.7	5.7
<i>Male</i>	(N = 58)		(N = 49)		(N = 50)		(N = 51)		(N = 50)		(N = 17)		(N = 38)	
Mandibular length (Co-Gn)	96.6	3.83	105.0	4.15	113.0	5.11	119.2	5.70	124.5	5.97	127.2	6.00	128.2	4.2
Midfacial length (Co-point A)	80.5	2.4	84.9	2.5	90.3	3.6	93.9	4.6	96.6	4.4	96.6	4.7	98.8	4.3
Maxillomandibular differential	16.1	—	20.1	—	22.7	—	25.3	—	27.9	—	30.6	—	29.4	—
Lower anterior facial height	59.9	2.7	63.0	3.0	65.7	2.5	68.8	4.0	71.3	4.4	73.1	4.4	72.0	3.0

**Table V.** Composite norms

Midfacial length (mm)	Mandibular length (mm)	Lower anterior facial height (mm)
80	97-100	57-58
85	105-108	60-62
90	113-116	63-64
95	122-125	67-69
100	130-133	70-74
105	138-141	75-79

mandible are excessively anteriorly positioned. Another problem can arise with the use of point A when there is excessive lingual tipping of the crown of the upper incisor, as in Class II, Division 2 malocclusions. In this case, the position of point A will be labially displaced by the labial tipping of the root. If so, a 1 to 2 mm adjustment can be made to reflect more accurately the position of the maxilla relative to the nasion perpendicular.

#### Relating the mandible to the maxilla (midface)

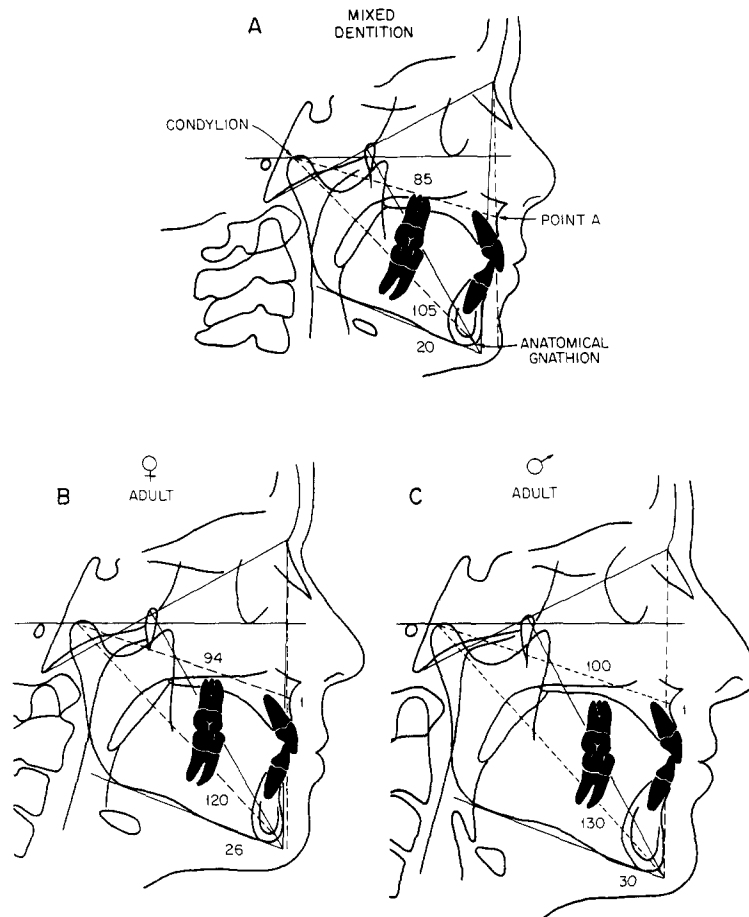
*Midfacial and mandibular lengths.* Next, the lengths of the mandible and the maxilla (or, more specifically, the midfacial region) are related. The midfacial and mandibular lengths can be determined by means of a modification of the method developed by Harvold.<sup>24, 25</sup> First the *effective* midfacial length, not the actual anatomic length of the maxilla, is determined by measuring a line from condylion (the most posterosuperior point on the outline of the mandibular condyle, Fig. 3) to point A. Then, the *effective* man-

dibular length is derived by constructing a line from condylion to anatomic gnathion (the most anteroinferior aspect of the mandibular symphysis). A geometric relationship exists between the effective length of the midface and that of the mandible. Any given effective midfacial length corresponds to a given effective mandibular length.

The reader may have concern about using condylion as a point of reference, since this landmark is often difficult to find. Two replies must be made to this concern. First, every effort should be made (for example, with a soft-tissue shield or an intensifying screen) to improve the quality of the radiographs routinely taken by the clinician. Second, condylion is used as a measure of the lengths of both the midface and the mandible. A slight error in the estimation of condylion will not dramatically affect the geometric relationship between the upper and lower jaws.

The relationship between the effective length of the midface and that of the mandible can be observed in the longitudinal studies of the Bolton standards (Table III) and of the Burlington Orthodontic Research Centre (Table IV). Composite norms (Table V) have been extrapolated from the values derived from the Bolton and Burlington samples, as well as from the Ann Arbor sample (Table I). These norms represent a geometric relationship between effective midfacial length and effective mandibular length and are not directly related to the age or sex of the individual subject.

Once the effective length of the midface is known, the effective mandibular length can be estimated. For example, a mixed-dentition subject with a balanced



**Fig. 3. A,** The determination of effective midfacial length and effective mandibular length in a mixed-dentition patient. **B,** Adult female. **C,** Adult male.

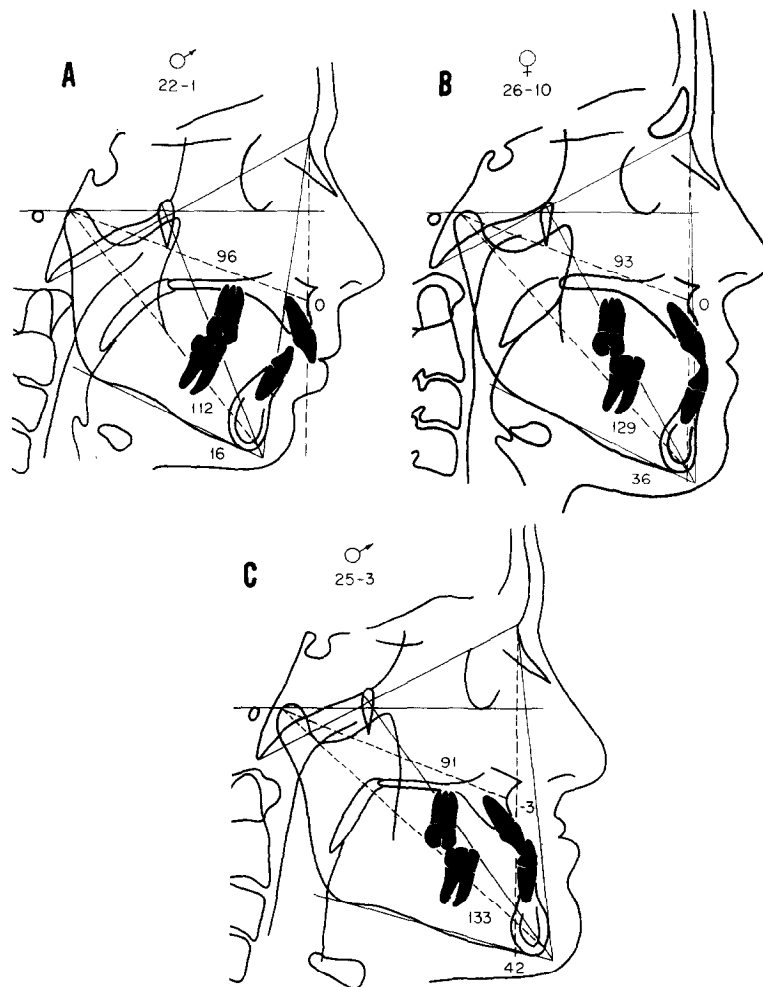
face has a maxilla (or effective midfacial length) 85 mm in length and a mandible 105 to 108 mm in length. If the effective midfacial length is subtracted from the mandibular length, the *maxillomandibular differential* can be determined. In this instance, the maxillomandibular differential is 20 to 23 mm (Fig. 3, A). The effective length of the midface of a medium-sized person, such as an adult female, is 94 mm and the effective length of the mandible is 120 to 123 mm (Fig. 3, B). In this case the maxillomandibular differential is 26 to 29 mm (Fig. 3, B). The effective midfacial length of a large person, such as an adult male, might be 100 mm and that of the mandible 130 to 133 mm, with a differential of 30 to 33 mm (Fig. 3, C). It is important to re-emphasize that the geometric relationship of the components, not the age of the patient, is the most important consideration.

Examples of variation in the relationship between midfacial and mandibular length will be demonstrated by three cases. Fig. 4, A shows a 22-year-old man who

had a Class II, Division 1 malocclusion. The effective length of his midface is 96 mm (see Table V); the effective length of his mandible, therefore, should be 123 to 126 mm. In fact, however, his mandible is approximately 12 mm too short, with the discrepancy primarily in the size of the mandible, since the maxilla is normally positioned relative to the nasion perpendicular.

Fig. 4, B shows a 26-year-old woman who has an effective midfacial length of 93 mm. The predicted effective length of the mandible for a midface of this size is 119 to 122 mm (Table V). According to the relationship of point A to the nasion perpendicular, the maxilla is normally positioned anteroposteriorly relative to the cranial base. Therefore, the mandible, at 129 mm, is approximately 10 mm too long.

Fig. 4, C shows a 25-year-old man who has a Class III malocclusion characterized clinically by a retrusive maxilla (indicated by the measurement of -3 mm from point A to the nasion perpendicular) and a prognathic



**Fig. 4.** **A**, Cephalometric tracing of a 22-year-old man with a skeletal mandibular deficiency of 12 mm. Maxillary position is normal. **B**, Cephalometric tracing of a 26-year-old woman with a skeletal mandibular excess of 10 mm. **C**, Cephalometric tracing of a 25-year-old man with a skeletal maxillary deficiency of 4 mm and a skeletal mandibular excess of 11 mm.

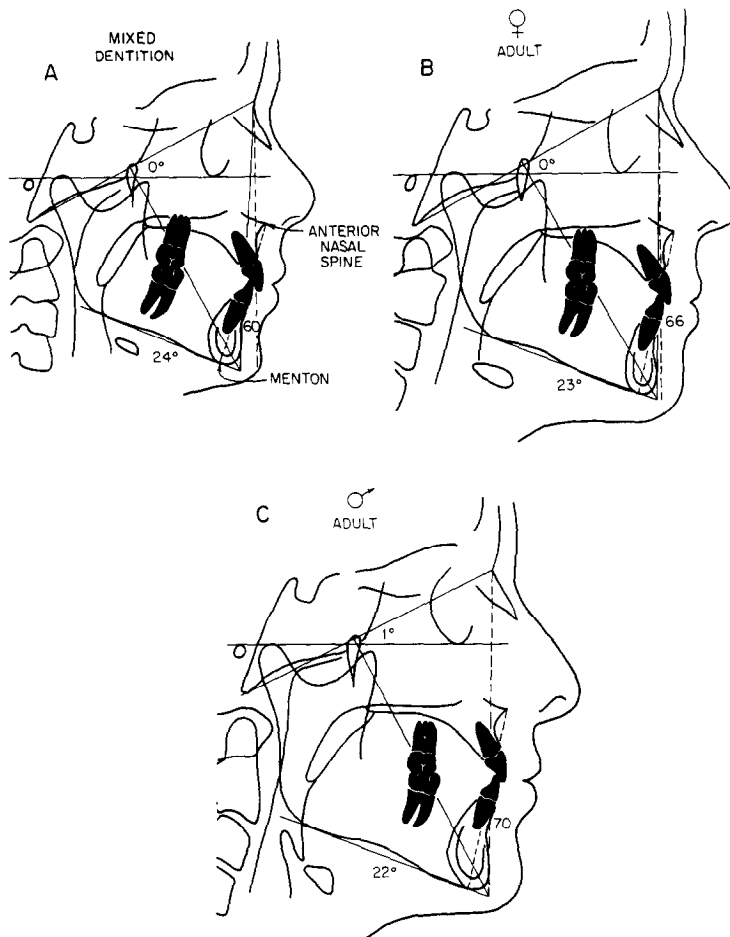
mandible. The maxillomandibular differential is about 11 mm greater than estimated. In this case the jaw discrepancy is due to a combination of a repositioning of the upper jaw and a forward position of the lower jaw.

*Vertical dimension.* The clinical appearance of the relationship between the upper and lower jaws is affected, to a great extent, by the lower anterior facial height. (*Note:* Upper anterior facial height is not considered here unless there is an obvious abnormality.) In this analytical method, lower anterior facial height is measured from anterior nasal spine to menton. This linear measurement increases with age and is correlated to the effective length of the midface (Tables I, IV, and V). The lower anterior facial height measurement for

an ideal mixed-dentition subject with an 85 mm effective midfacial length is 60 to 62 mm (Fig. 5, *A*). An effective midfacial length of 94 mm (Fig. 5, *B*) corresponds to a lower anterior facial height of 66 to 68 mm in a subject of medium size. In a large person with an effective midfacial length of 100 mm, lower facial height is approximately 70 to 74 mm as is shown in Fig. 5, *C*.

An increase or decrease in the lower anterior facial height can have a profound effect on the horizontal relationship of the maxilla and mandible. For example, if the mandible is rotated downward and backward concomitant with a 15 mm increase in lower anterior facial height (Fig. 6, *A*), the chin point moves away from the nasion perpendicular. In the example seen in Fig. 6, *A*,



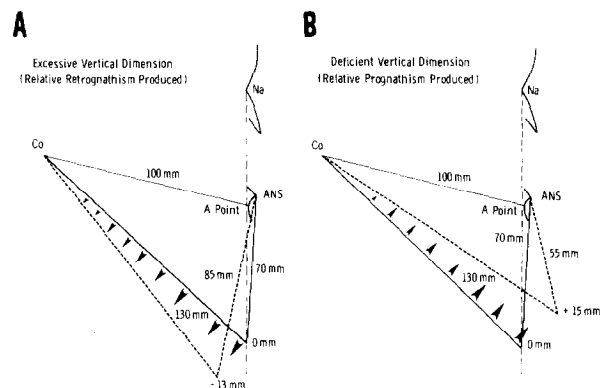


**Fig. 5.** A determination of lower anterior facial height as measured from anterior nasal spine to menton. **A,** Ideal mixed dentition. **B,** Ideal adult female. **C,** Ideal adult male.

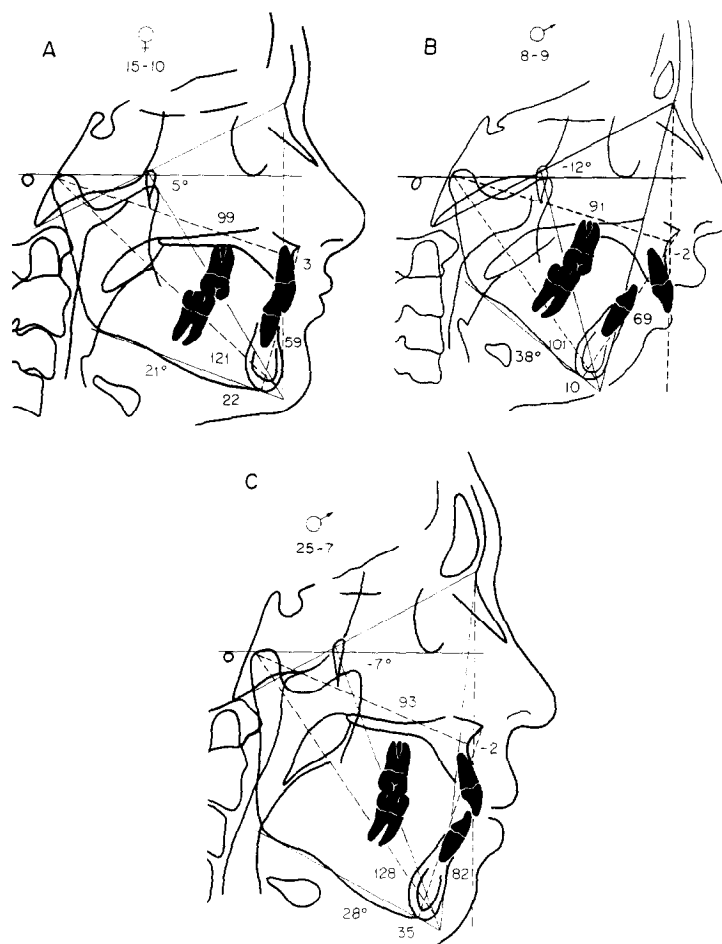
the chin point is moved posteriorly 13 mm as a result of the rotation. If the anterior facial height is shortened by 15 mm (Fig. 6, B), autorotation of the mandible will move the chin point forward by 15 mm.

If lower anterior facial height is increased, the mandible will appear to be more retrognathic. If lower anterior facial height is decreased, the mandible will appear to be more prognathic. In a growing person an increase in lower anterior facial height will camouflage a similar increase in mandibular length, which may result in the appearance that the chin is in the same relationship anteroposteriorly to cranial base structures.

Fig. 7, A shows the cephalometric tracing of a 15-year-old girl with a Class II, Division 2 malocclusion. The effective length of the midface is 99 mm (this length can be reduced by about 2 mm because of the anterior position of the root of the maxillary incisors).



**Fig. 6.** **A,** The relationship between lower anterior facial height and effective mandibular length. An excessive vertical dimension of 15 mm produces an effective mandibular retraction of 13 mm. **B,** The reduction in vertical dimension of 15 mm produces a relative mandibular protrusion of 15 mm.

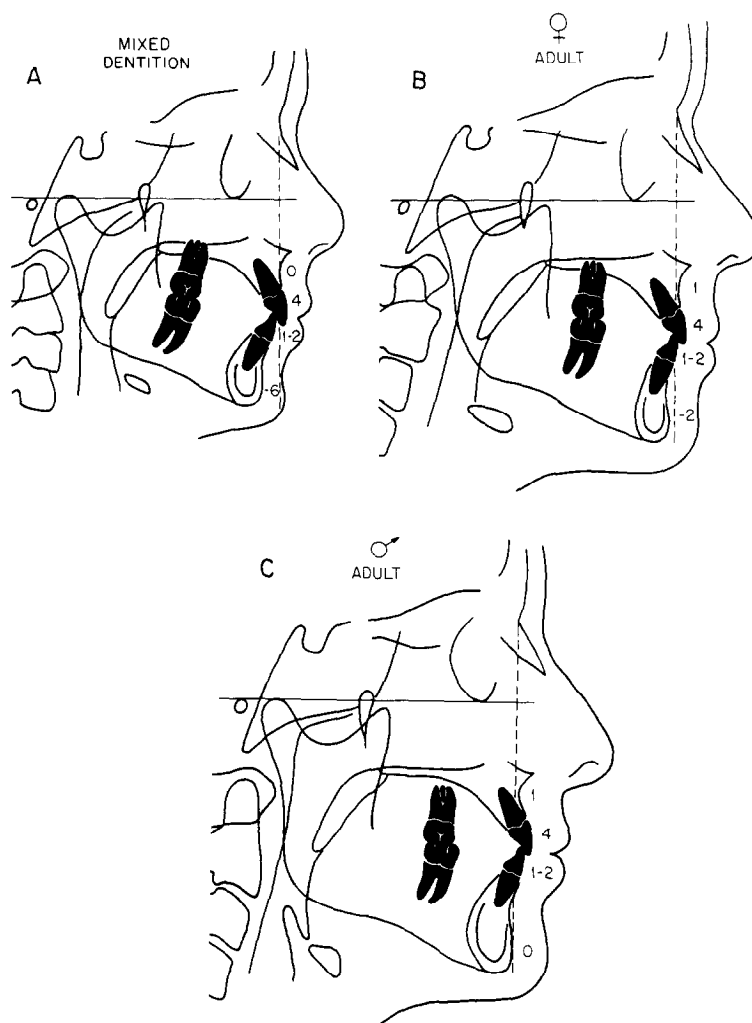


**Fig. 7. A,** Cephalometric tracing of a 15-year-old girl with a Class II, Division 2 malocclusion. The labial position of the root of the maxillary central incisor necessitates the adjustment in effective maxillary length by reduction of that length from 99 to 97 mm. This indicates a relative mandibular deficiency of 8 mm, which is masked by a forward rotation of the mandible. The patient has a 5° facial axis angle and a relatively low mandibular plane angle. **B,** Cephalometric tracing of an 8-year-old boy with mild maxillary skeletal retrusion (-2 mm) and a deficiency in effective mandibular length of 16 mm. The patient appears more retrognathic because of the 5 mm excess in lower facial height. **C,** Cephalometric tracing of a 25-year-old man. The patient has a relative maxillary skeletal retrusion of -2 mm and a mandibular skeletal protrusion of 7 mm. However, the patient appears retrognathic because of the 15 mm excess in lower anterior facial height.

If the adjusted *effective* length of the midface is 97 mm, then the *effective* mandibular length is expected to be approximately 126 to 128 mm. Even though the actual effective mandibular length is 5 or 6 mm short of the expected value, pogonion lies on the nasion perpendicular. The explanation for this observation is that the patient has a deficient anterior facial height of 6 or 7 mm, which allows for autorotation of the mandible into a more forward position, thus masking the severity of the mandibular deficiency. If lower anterior facial height were correct, pogonion would be 6 to 7 mm posterior to the nasion perpendicular.

A patient with a severe skeletal discrepancy is seen in Fig. 7, *B*. This 8-year-old boy has a slightly retrusive maxilla and a severely retruded mandible. The chin appears further retruded because of an excess in lower anterior facial height.

Fig. 7, *C* shows a 25-year-old man with a 93 mm effective midfacial length. The corresponding effective mandibular length should be approximately 119 mm (Table V), but the patient's effective mandibular length is 128 mm. This indicates that the mandible is prognathic. However, since the lower anterior facial height is 82 mm (about 15 mm greater than expected), the net



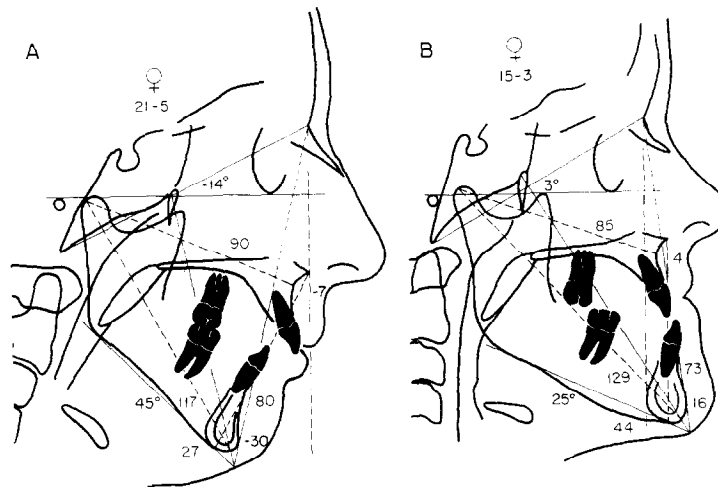
**Fig. 8.** The position of pogonion and of the upper and lower incisors in a balanced face. Regardless of the patient's age, the upper incisors should be 4 to 6 mm ahead of a line dropped from perpendicular to Frankfort horizontal through point A. The facial surface of the lower incisor should be 1 to 3 mm ahead of a line constructed from point A to pogonion. The distance from pogonion to the nasion perpendicular is variable according to the age of the patient. **A**, Ideal mixed dentition. **B**, Ideal adult female. **C**, Ideal adult male.

effect of the excessive mandibular length and the even greater excess in anterior facial height is the appearance of a long face with an apparent mandibular retrusion. Once again, lower anterior facial height is altering the appearance of the horizontal relationship of the maxilla and the mandible. It is clear that, because of the interrelationship of lower anterior facial height and the anteroposterior position of pogonion, one must assess lower anterior facial height before classifying a given malocclusion.

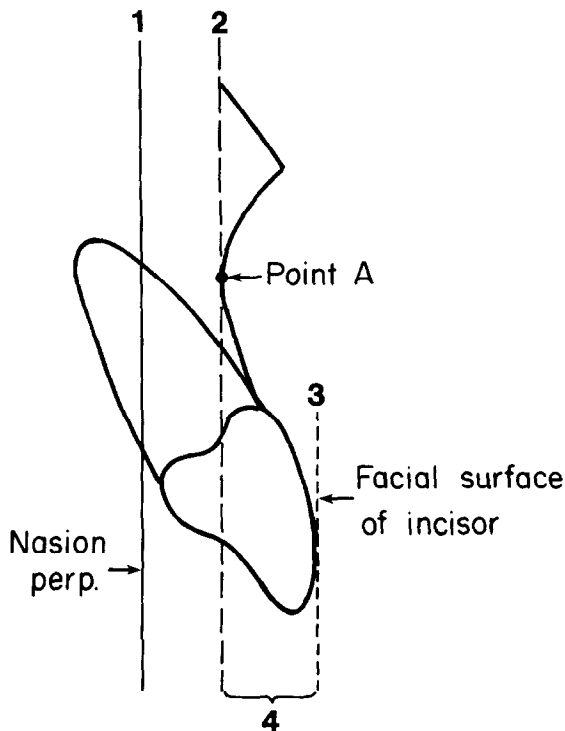
Incidentally, confusion can be avoided by using specific terms to describe skeletal relationships. For example, the term *Class II skeletal relationship* is a

misnomer. Also, the term *mandibular skeletal retrusion* is not synonymous with *Class II malocclusion*. The Angle classification, which is useful in identifying dental malocclusion, is inadequate for describing the accompanying skeletal relationships. Skeletal relationships are best characterized by specific, descriptive terms, such as *mandibular skeletal retrusion*, *maxillary skeletal protrusion*, and *excessive lower anterior facial height*.

Two other measurements are shown in Fig. 7; they are the mandibular plane angle (the angle between the anatomic Frankfort plane and the mandibular plane, gonion-menton) and the facial axis angle of Ricketts.<sup>10, 11</sup>



**Fig. 9. A,** Cephalometric tracing of a patient with maxillary skeletal retrusion and severe mandibular skeletal retrusion and excessive anterior facial height. **B,** Cephalometric tracing of a 15-year-old girl with mandibular prognathism. This is an example of a Class III patient who appeared clinically to be deficient in the upper facial area, particularly at nasion. Therefore, the nasion perpendicular is posteriorly positioned and is subject to adjustment.

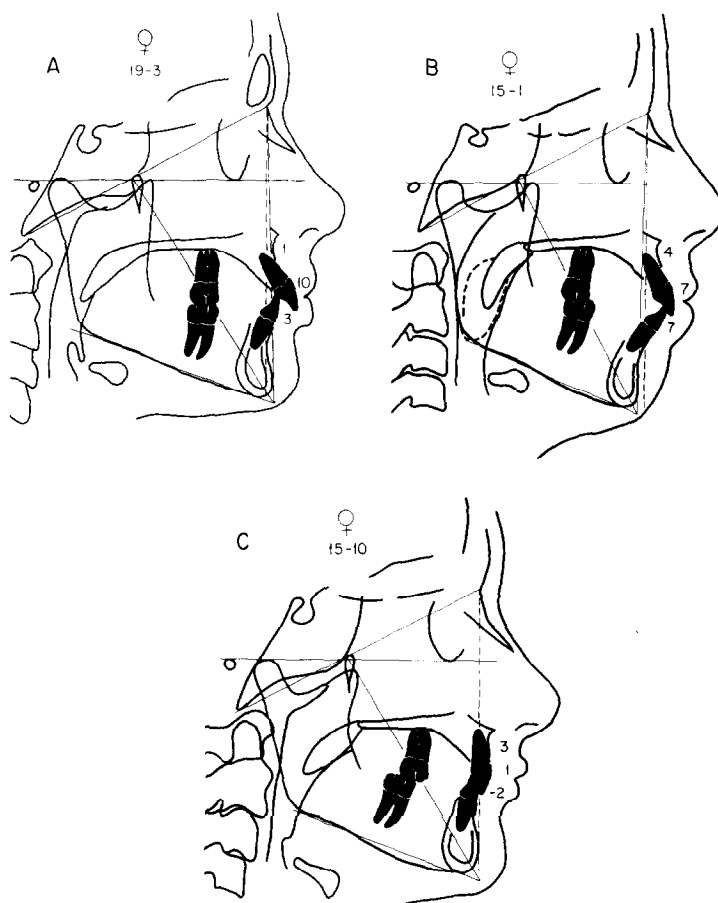


**Fig. 10.** Determination of the anteroposterior position of the upper incisor relative to point A. This measurement should be 4 to 6 mm. 1, Nasion perpendicular. 2, Point A perpendicular constructed parallel to the nasion perpendicular through point A. 3, Line drawn parallel to the nasion perpendicular through the most anterior surface of the upper incisor. 4, The anteroposterior distance from the upper incisor to point A.

The latter measurement is determined by constructing a line from basion to nasion, a line which represents the cranial base. Then a second line (the facial axis) is constructed from the posterosuperior aspect of the pterygomaxillary fissure (PTM) to constructed gnathion (the intersection of the facial plane and the mandibular plane.) A perpendicular relationship of the basion-nasion line and the facial axis is to be expected in a balanced face. As the facial axis angle deviates from 90° in its relationship to the cranial base, horizontal or vertical facial development can be assessed (the angle measured is that formed by basion-PTM-gnathion). Excessive vertical development is indicated by negative values (values less than 90°), and deficient vertical facial development is indicated by positive values (values greater than 90°).

**Relating the mandible to the cranial base**

The relationship of the mandible to the cranial base is determined by measuring the distance from pogonion to the nasion perpendicular. For example, in a mixed-dentition subject with a balanced face, pogonion lies posterior (-8 mm to -6 mm) to the nasion perpendicular (Fig. 8, A, Table II). In a person with a medium-sized maxillary length (Fig. 8, B), pogonion usually lies -4 mm to 0 mm relative to the nasion perpendicular (Tables I and II). In a larger person, such as an adult male, the measurement of the chin position is usually -2 mm to 2 mm relative to the nasion perpendicular (Fig. 8, C, Tables I and II).



**Fig. 11.** **A**, Patient with a normal maxillary position and protruded upper teeth. The upper incisors are 5 to 6 mm forward of their ideal position. The lower incisors are slightly anterior but positioned within normal limits relative to the A-Po line. **B**, Patient with maxillary skeletal protrusion and protrusion of the upper and lower dentition. **C**, Patient with retruded upper and lower incisors.

Fig. 9, *A* shows an example of an adult patient with a retrusive maxilla, a retrusive mandible, a steep mandibular plane angle, and a -30 mm distance from pogonion to the nasion perpendicular. A prognathic patient with the pogonion positioned 16 mm ahead of the nasion perpendicular is shown in Fig. 9, *B*.

#### Relating the upper incisor to the maxilla

*Anteroposterior position.* In cases of malrelationships between the maxillary and mandibular skeletal structures, serious errors may result if the position of the upper incisor is determined by any measurement that uses the mandible as a point of reference. An example is the A-pogonion line.<sup>10-12</sup> This can be a common error since, in a study of 277 8- to 10-year-olds with Class II malocclusions,<sup>35</sup> 50% to 70% had a skeletal mandibular retrusion. In this example, the mandible is used as a reference for maxillary incisor

position *only* if the unchanged position of the mandible is accepted as a treatment goal.

A similar statement can be made regarding any measure that uses cranial base structures for reference to determine the position of the upper incisor. For example, a measurement of upper incisor to the N-A line<sup>5-7</sup> is valid only if the maxilla is in a neutral position anteroposteriorly relative to the cranial base. A retrusive position of the maxilla relative to nasion will make the incisor appear more protrusive, whereas a protrusive position of the maxilla will make the upper incisors appear more retrusive.<sup>36</sup>

The position of the upper incisor can be located by using measurements that relate the dental portion of the maxilla to the skeletal portion of the maxilla. This is accomplished by drawing a vertical line through point A, parallel to the nasion perpendicular (Fig. 10). The distance from this constructed *point A perpendicular* to

**Table VI.** Dental variables from the Bolton standards (mm) (N = 16 for each sex at each age, standardized 8% enlargement)

	6 years		9 years		12 years		14 years		16 years		18 years	
	$\bar{X}$	SD	$\bar{X}$	SD	$\bar{X}$	SD	$\bar{X}$	SD	$\bar{X}$	SD	$\bar{X}$	SD
<i>Female</i>												
Maxillary dental (upper incisor to point A)	-2.1	1.4	2.9	0.9	3.3	1.0	4.2	1.5	4.0	1.3	4.2	1.3
Mandibular dental (lower incisor to A-Po line)	0.02	1.4	0.9	1.1	1.3	0.7	1.4	1.6	1.1	1.6	1.2	1.4
<i>Male</i>												
Maxillary dental (upper incisor to point A)	0.8	1.4	3.1	1.3	3.8	1.3	3.8	1.4	4.1	2.1	3.7	1.3
Mandibular dental (lower incisor to A-Po line)	0.5	1.3	1.1	1.5	1.4	1.6	1.4	1.8	1.3	2.3	0.4	1.8

the facial surface of the upper incisor is measured. The measurement from point A to the facial surface of the upper incisor horizontally is 4 to 6 mm (Fig. 8, Tables I and II). Fig. 11, *A* shows a patient who has a protruded upper incisor and a relatively normally positioned maxilla. Fig. 11, *B* shows a patient with maxillary skeletal protrusion and maxillary dentoalveolar protrusion. A patient with retruded upper incisors is illustrated in Fig. 11, *C*.

*Vertical position.* The vertical position of the upper incisor is best determined at the time of the clinical examination, although a head film taken with the lips at rest may also be useful. Typically, the incisal edge of the upper incisor lies 2 to 3 mm below the upper lip at rest. However, some adjustment may be made in interpreting the meaning of this measurement according to the functional state of the lip musculature and the axial inclination of the tooth prior to treatment.

#### Relating the lower incisor to the mandible

Relating the lower incisor to the mandible is analogous to relating the upper incisor to the maxilla. Both the anteroposterior and the vertical positions are considered.

*Anteroposterior position.* The anteroposterior position of the lower incisor can be determined by using a traditional version of the Ricketts<sup>10-12</sup> measurement of the facial surface of the lower incisor to the A-pogonion line (Fig. 8). The facial surface of the lower incisor lies 1 mm to 3 mm anterior to the A-pogonion line. In a well-balanced face, such as those comprising the Bolton standards (Table VI), the facial surface of the lower incisor is approximately 1.5 mm anterior to the A-pogonion line. In the Ann Arbor sample (Table I), the lower incisor is in a slightly more protrusive position (2.3 to 2.7 mm). If a discrepancy in anteropos-

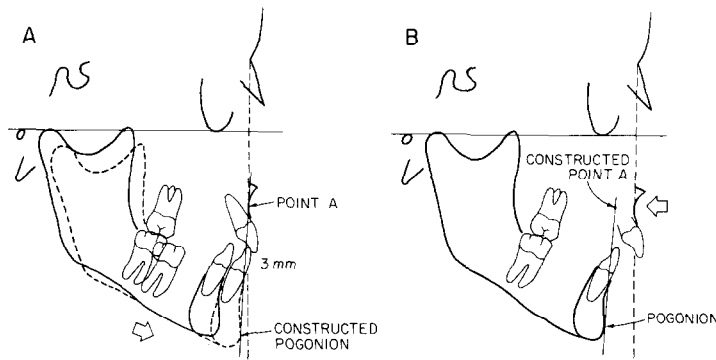
terior or vertical positioning of the mandible and maxilla exists, then modifications in this measurement procedure become necessary, as will be described below.

In order to predict the anteroposterior position of the incisor after functional or surgical intervention, a second tracing of the mandible and the incisor is made, and the tracing is moved so that the mandible is in the desired position relative to the maxilla (Fig. 12, *A*). A new line from point A to pogonion is drawn. The incisor is expected to lie 1 to 2 mm anterior to the constructed A-Po line.

Another way in which the lower incisor position can be determined relative to a constructed A-pogonion line is to first estimate the number of millimeters that the mandible will be brought forward relative to the maxilla at the end of treatment. Then a new point A is constructed the same number of millimeters in the opposite direction (Fig. 12, *B*). This provides an approximate posttreatment A-pogonion line which can then be used to evaluate the predicted lower incisor position without making a template tracing.

Fig. 11, *B* shows a patient with maxillary and mandibular incisal protrusion. This is indicated by a 7 mm relationship of the upper incisor to the maxilla and a 7 mm relationship of the lower incisor to the A-pogonion line. Fig. 11, *C* shows a patient who has dentoalveolar retrusion in both arches.

*Vertical position of the lower incisor.* The vertical position of the lower incisor is evaluated on the basis of the existing lower anterior facial height. The pretreatment overbite relationship is first evaluated by relating the lower incisor tip to the functional occlusal plane. If there is an excessive curve of Spee, a decision must be made as to whether the lower incisor should be intruded or the lower molar should be allowed to erupt. The



**Fig. 12.** Determination of lower incisor position in cases with existing skeletal discrepancies. **A,** A tracing of the existing position of the mandible is made and is moved so that the mandible is in the expected position relative to the maxilla and cranial base. An idealized A-Po line can be constructed. In this example, the lower incisor now lies 3 mm ahead of the idealized A-Po line. **B,** The amount of desired anterior movement of pogonion is measured. Point A is then moved in the opposite direction the same amount. The idealized A-Po line is constructed through the new point A and the existing pogonion, and the position of the lower incisor is then measured.

determining factor is lower anterior facial height relative to the effective midfacial length (Table V). If the existing lower anterior facial height is either excessive or normal, the lower incisor is *intruded*. If, on the other hand, lower anterior facial height is inadequate and the lower incisor is extruded, further *eruption* of the molar is desired.

Anterior repositioning of the mandible in a patient with a deep overbite (as occurs following an anterior surgical advancement of the mandible or during functional appliance treatment) will require a significant increase in lower facial height. This repositioning may be detrimental to patients with normal or excessive lower anterior facial heights. If so, the mandibular incisors are intruded. However, a patient who has an inadequate lower anterior facial height and a deep bite may benefit from anterior and inferior repositioning of the mandible to an edge-to-edge incisor position, followed by posterior tooth eruption. Such eruption would then close the transient posterior open bite. Through the anteroposterior and vertical control of the position of the lower incisor, repositioning of the osseous elements can be maximized.

### Airway analysis

Two measurements are used to examine the *possibility* of an airway impairment.

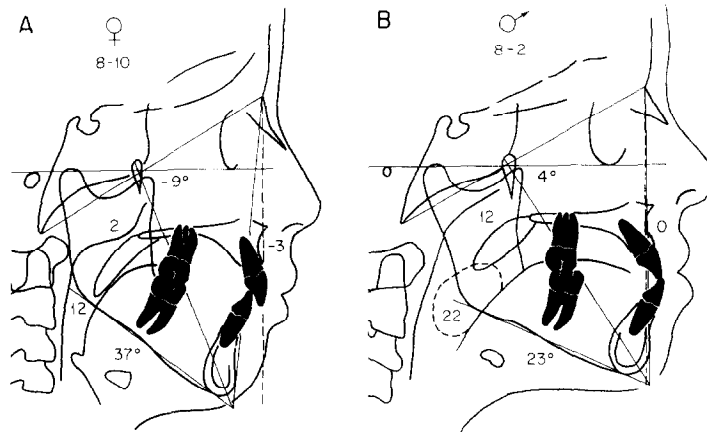
**Upper pharynx.** The upper pharyngeal width is measured from a point on the posterior outline of the soft palate to the closest point on the posterior pharyngeal wall. This measurement is taken on the anterior half of the soft palate outline because the area immediately adjacent to the posterior opening of the nose is

critical in determining upper respiratory patency. The head film outline of the nasopharynx is a two-dimensional representation of a three-dimensional structure.

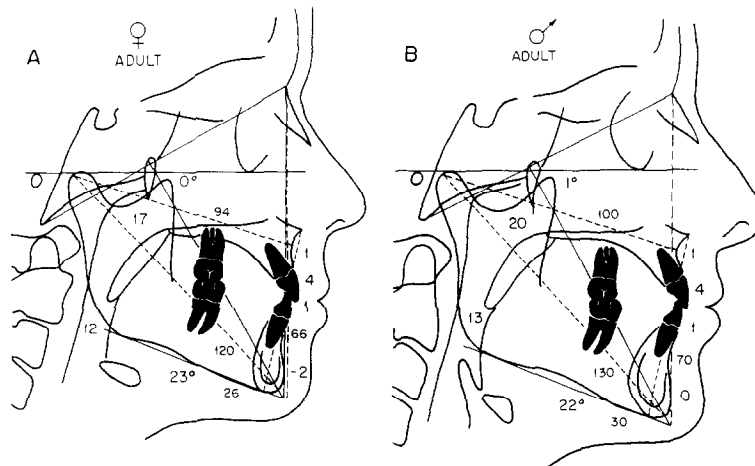
If a patient is swallowing when the radiograph is taken, the soft palate takes on the appearance of an inverted V, as the tensor and levator veli palatini muscles pull the palate upward and backward during closure. This configuration of the soft palate suggests only limited usefulness of the upper pharyngeal measurement.

Apparent airway obstruction, as indicated by an opening of 5 mm or less in the upper pharyngeal measurement, is used only as an indicator of possible airway impairment. A more accurate diagnosis can be made only by an otorhinolaryngologist during a clinical examination. In the Ann Arbor sample, the average upper airway measurement for adults of both sexes is 17.4 mm. This measure increases with age. Fig. 13, *A* shows a patient who demonstrates possible adenoid obstruction of the upper airway, as upper pharyngeal width is only 2 mm. A typical upper pharyngeal measurement in a mixed-dentition patient is shown in Fig. 13, *B*.

**Lower pharynx.** Lower pharyngeal width is measured from the intersection of the posterior border of the tongue and the inferior border of the mandible to the closest point on the posterior pharyngeal wall. According to the measures derived from the Ann Arbor sample (Table I), the average value for this measurement is 10 to 12 mm and does not change appreciably with age. In contrast to the upper pharynx, a smaller than average value for the lower pharynx is not remarkable. It is rare



**Fig. 13. A,** Determination of possible upper airway obstruction in a patient with an excessive adenoidal mass. The distance between the posterior aspect of the soft palate and the closest point on the posterior pharyngeal wall is 2 mm. The lower airway measurement is within normal limits (12 mm). Note that this patient has a steep mandibular plane angle and a negative facial axis angle. **B,** Patient with enlarged tonsils and a forward tongue position. The distance from the intersection of the posterior outline of the tongue and the lower border of the mandible and the closest point on the posterior pharyngeal wall is 22 mm. The upper airway measurement of 12 mm is within normal limits. This patient has a positive facial axis angle and a relatively normal mandibular plane angle.



**Fig. 14.** Combined values for the adult patient. **A,** Ideal female. **B,** Ideal male.

to see an obstruction of the lower pharyngeal area because of the position of the tongue against the pharynx. However, a lower pharyngeal width of greater than 15 mm suggests anterior positioning of the tongue, either as a result of habitual posture or due to an enlargement of the tonsils.

Determination of tongue position is important in the diagnosis of certain clinical conditions, such as mandibular prognathism, dentoalveolar anterior crossbite, or bialveolar protrusion of the teeth. These clinical conditions can be associated with a forward tongue position and/or enlarged tonsils. Fig. 13, *A* shows a patient with a normal lower pharyngeal measurement.

Fig. 13, *B* shows a patient with excessive lower pharyngeal width and a forward position of the tongue. (Cephalometric measurements of the anteroposterior and superoinferior size of the tonsils can also be made.)

All measurements outlined in the above text are combined in Fig. 14 for adult patients. The growing patient is considered below.

**ANALYSIS OF SERIAL FILMS**

The following analytical steps are used to assess growth or treatment changes occurring between serial head films.

Fig. 15, *A* shows a tracing of a head film of an ideal



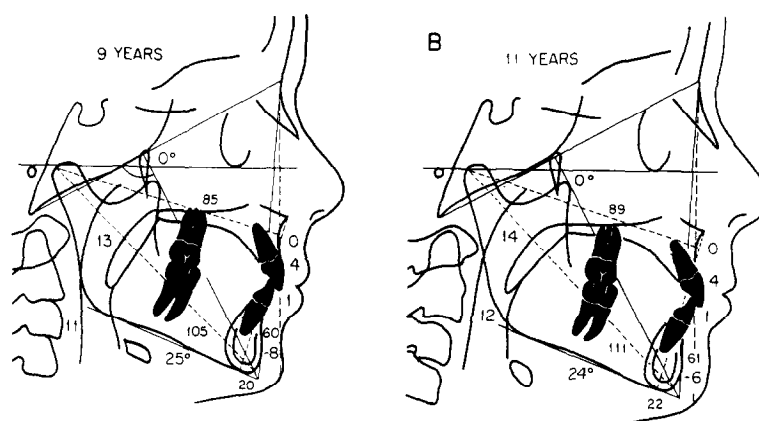


Fig. 15. A, Cephalometric tracing of ideal 9-year-old. B, Cephalometric tracing of the same ideal patient 2 years later.

Table VII. Annual changes in length (mm) from the Bolton standards (N = 16 for each sex at each age, standardized 8% enlargement)

	6-9 years		9-12 years		12-14 years		14-16 years		16-18 years	
	$\bar{X}$	SD	$\bar{X}$	SD	$\bar{X}$	SD	$\bar{X}$	SD	$\bar{X}$	SD
<i>Female</i>										
Mandibular length (Co-Gn)	2.4	0.7	2.6	0.7	2.5	0.7	1.4	0.7	0.6	0.5
Midfacial length (Co-point A)	1.6	0.2	1.7	0.5	1.1	0.7	0.7	0.6	0.3	0.4
Maxillomandibular differential	-0.8	0.6	-0.8	0.4	-1.3	0.4	-0.6	0.4	0.2	0.4
Lower anterior facial height	0.6	0.3	0.9	0.3	0.9	0.4	0.8	0.5	0.4	0.6
<i>Male</i>										
Mandibular length (Co-Gn)	2.8	0.6	2.2	0.7	3.1	1.3	3.3	1.1	1.8	1.5
Midfacial length (Co-point A)	1.8	0.5	1.6	0.6	1.8	0.9	1.8	1.0	0.9	0.8
Maxillomandibular differential	0.0	0.4	0.1	0.4	-0.2	0.8	-0.4	0.6	-0.3	0.7
Lower anterior facial height	0.9	0.3	0.8	0.6	1.0	0.8	1.7	0.7	1.2	0.8

9-year-old. The effective length of the midface is 85 mm, the effective length of the mandible is 105 mm, and the maxillomandibular differential is 20 mm. Lower anterior facial height is 60 mm. The maxilla is in its expected relationship to the cranial base (0 mm to the nasion perpendicular), the upper incisor is in its expected position relative to the maxilla (4 mm to the point A vertical), and the lower incisor is ideally positioned with respect to the mandible (1 mm to point A-pogonion). The mandibular plane angle and the facial axis angle of Ricketts<sup>10-12</sup> are also shown. Fig. 15, B presents a tracing of this patient 2 years later. It is estimated that the effective length of the midface will increase approximately 1 to 2 mm per year, the effective length of the mandible will increase approximately 2 to 3 mm per year, and anterior facial height will increase approximately 1 mm per year.

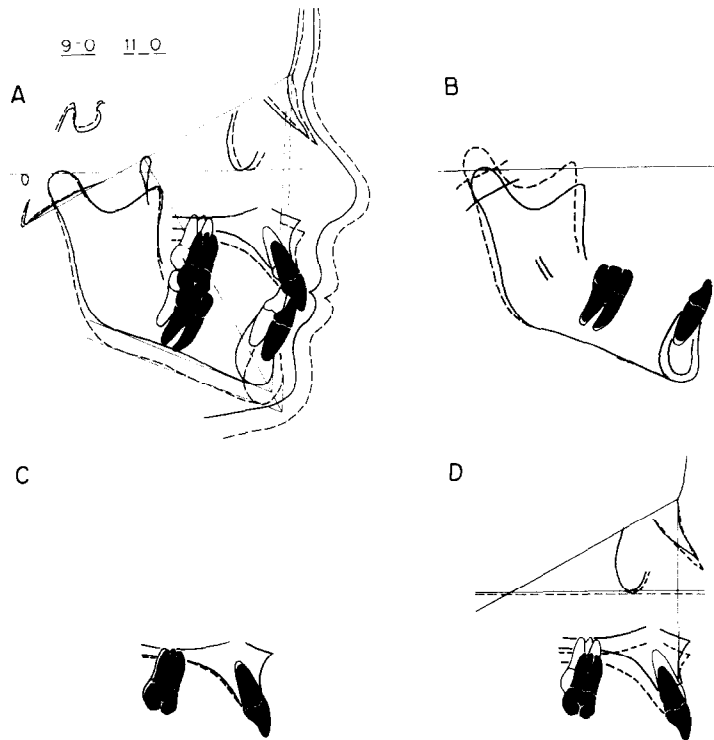
An analysis of the incremental values derived from the Bolton standards indicates evidence of sexual di-

morphism and age-related differences in growth increments. Midfacial and mandibular lengths increase steadily in girls until about age 14, at which time the rate of growth drops dramatically (Table VII). In contrast, male subjects demonstrated growth increments to the oldest ages studied (18 years), with the highest rates of growth occurring between ages 12 and 16.

The relationships of the maxilla to the cranial base, of the upper incisor to the maxilla, and of the lower incisor to the mandible do not change during the 2-year time period evaluated. The distance from pogonion to the nasion perpendicular usually decreases approximately 0.5 to 1 mm per year. The facial axis angle remains relatively unchanged, while the mandibular plane angle decreases slightly.

#### Superimposition technique

In the analysis of serial films, great care must be taken to ensure that identification of landmarks in sub-



**Fig. 16.** **A**, The overall changes in facial growth are indicated by superimposing subsequent tracings along the basion-nasion line at the intersection of the pterygomaxillary fissure. **B**, Changes in the mandible and the mandibular dentition can be displayed by superimposing serial tracings on internal structures. **C**, Changes in the maxilla and the maxillary dentition can be examined by superimposing serial tracings on internal structures. **D**, The measurement of anteroposterior maxillary displacement can be determined by superimposing serial tracings along the basion-nasion line at nasion.

sequent films is consistent. Thus, the four-point superimposition method of Ricketts<sup>10, 11</sup> is used not only to analyze growth changes but also to check for errors in landmark identification.

**Cranial base superimposition.** The first superimposition (Fig. 16, *A*) is along the basion-nasion line at the posterosuperior aspect of the pterygomaxillary fissure. It shows the downward and forward movement of the facial structure during the 2-year period. The chin moves downward and forward, as do the maxillary and mandibular teeth. A relatively parallel progression of the profile in a downward and forward direction is also observed.

**Mandibular superimposition.** Superimposition of the mandible, using internal structures such as the outline of the inferior alveolar canal and the lingual surface of the symphysis (Fig. 16, *B*), demonstrates the amount of eruption and horizontal movement of the mandibular teeth. The amount and direction of condylar growth and the degree of localized remodeling also can be measured.

**Maxillary superimposition.** Superimposition of the maxilla on internal structures (Fig. 16, *C*) shows the movement of the maxillary dentition and the amount of localized remodeling that occurred in the various regions of the maxilla.

**Maxillary displacement.** Superimposition along the basion-nasion line at nasion (Fig. 16, *D*) allows evaluation of the position of the maxillary complex relative to the upper face. As mentioned earlier, nasion and point A move forward at approximately the same rate during growth. With this type of superimposition, downward movement is observed in a growing person, but there is little forward or backward movement.

The effect of treatment on the maxilla also can be measured when this method of superimposition is used. Point A may be moved forward after the use of an orthopedic appliance, such as a facial mask or reverse-pull chin cup. Conversely, if an orthopedic headgear is used to move the maxilla posteriorly, point A would appear to be displaced posteriorly in the second tracing.

## DISCUSSION

The advantages of using the method of cephalometric analysis described in this article are summarized below.

1. This method depends primarily upon linear measurements rather than angles, so that treatment planning (particularly treatment planning for the orthognathic surgery patient) is made easier. Cephalometric enlargement must be known if the normative data are to be used correctly.

2. This method of analysis is more sensitive to vertical changes than is an analysis which relies on the ANB angle, such as that of Steiner.<sup>5-7</sup> The use of the ANB angle can be misleading, since it tends to be insensitive to the vertical component of jaw discrepancies. Similarly, changes in growth pattern, which include both horizontal and vertical adaptations, may be completely missed if only a change in the ANB angle is measured.

3. This analytical procedure provides guidelines with respect to normally occurring growth increments. Therefore, the norms derived from the Bolton standards, the Burlington sample, and the Ann Arbor sample and the composite norms presented in this article can be used to evaluate treatment results.

4. The principles of this analysis are easily explained to nonspecialists and to lay persons such as patients and parents.

This analysis has proved to be useful in a variety of clinical situations. Certainly, not all possible measurements are included in this analysis. Therefore, variations and additions to the analysis may be made by each practitioner. The analysis described provides the clinician with a specific method which assists in the diagnosis, treatment planning, and treatment evaluation of clinical patients.

## STEP-BY-STEP PROCEDURE

The previous presentation of this analysis has been conceptual rather than practical. The actual performance of the analysis is carried out in an order derived from the ease of tracing the cephalogram. The following is a description of the step-by-step procedures involved in doing the static and dynamic parts of the analysis.

### Analysis of a single film

This part of the procedure is used to evaluate a single head film and should be carried out in sequence.

1. Draw the outline of the soft-tissue profile.
2. Identify anatomic porion (the most superior aspect of the external auditory meatus) and or-

bitale (the most inferior point on the bony orbit).

3. Draw the Frankfort horizontal.
4. Define the nasal structures, including nasion.
5. Construct the nasion perpendicular.
6. Define the outline of the maxilla.
7. Define the outline of the mandible, including the mandibular condyle.
8. Define the maxillary and mandibular teeth.
9. Measure the following distances:
  - a. Point A to the nasion perpendicular (ideal is 0-1 mm).
  - b. Point A vertical to the facial surface of the upper incisor (ideal is 4-6 mm).
  - c. Facial surface of the lower incisor to the point A-pogonion line (ideal is 1-3 mm).
  - d. Pogonion to the nasion perpendicular (ideal: small, -8 to -6 mm; medium, -4 to 0 mm; large, -2 to 2 mm).
10. Identify the pterygomaxillary fissure and basion.
11. Construct:
  - a. The basion-nasion line.
  - b. The facial plane (nasion-pogonion).
  - c. The mandibular plane (gonion-menton).
12. Construct the facial axis by connecting the most posterosuperior aspect of the pterygomaxillary fissure (PTM) with constructed gnathion, the intersection of the facial and mandibular planes.
13. Measure the facial axis angle (basion-PTM-gnathion) and subtract this value from 90°. Zero degrees (90°) is the normal value for this measure.
14. Measure the angle between the mandibular plane and the Frankfort horizontal.
15. Identify condylion (the most posterosuperior of the condylar outline).
16. Measure the effective midfacial length (condylion-point A) and the effective mandibular length (condylion-anatomic gnathion). All normative values include an 8% enlargement factor.
17. Subtract the effective midfacial length from the effective mandibular length, determining the maxillomandibular differential (ideal: small, 20 mm; medium, 25-27 mm; large, 30-33 mm).
18. Identify anterior nasal spine and menton. Measure the distance between these two landmarks (ideal: small, 60-62 mm; medium, 65-67 mm; large, 70-73 mm).
19. Define the posterior pharyngeal wall, the soft

palate, and the posterior border of the tongue.

20. Bisect the distance from posterior nasal spine to the tip of the soft palate. Measure the closest distance from the anterior half of the soft palate to the posterior pharyngeal wall (measurements of less than 5 mm are of concern).
21. Identify the intersection point between the posterior outline of the tongue and the inferior border of the mandible (near the gonial angle).
22. Measure the distance from this intersection point to the posterior pharyngeal wall (average values, 10-12 mm). Any value over 15-16 mm is of concern. Larger than normal values are usually accompanied by an enlarged tonsil, which usually can be observed radiographically.

### Analysis of serial films

As mentioned earlier, the four-point superimposition of Ricketts<sup>10-11</sup> is used in the analysis of longitudinal records. The sequence of superimposition is important, since each superimposition acts as a check to make sure that the tracings are done correctly. The first superimposition is along the internal structures of the maxilla. This determines the amount of tooth movement relative to the maxilla, and it ensures that the upper teeth have been properly traced in the two films. For example, intrusion of the maxillary molars would not be seen on the second film unless the therapy undertaken involved intrusion. Next, the amount of maxillary displacement is determined by superimposing along the basion-nasion line at nasion. The third step is to superimpose the tracings on the internal structures of the mandible. Usually the inferior alveolar canal or the lingual border of the symphysis (or, in young patients, the third molar crypt) can be identified. The last superimposition used is the cranial base superimposition, which allows an overall evaluation of the treatment effects.

The author would like to thank Dr. Rolf G. Behrents and Dr. B. Holly Broadbent, Jr., for the use of the data from the Bolton-Brush Study at Case Western Reserve University and Dr. Frank Popovich of the University of Toronto for providing data from the Burlington Growth Centre. In addition, the author thanks Dr. Robert M. Ricketts and the Foundation for Orthodontic Research for contributing films to the Ann Arbor sample. The author also thanks Dr. Raymond P. Howe, Dr. Robert P. Scholz, Dr. Brainerd F. Swain, and Dr. Edward Ellis III for their helpful suggestions during the development of this analysis. Thanks also to Dr. Fred L. Bookstein, Ms. Katherine A. Ribbens, and Dr. Peter S. Vig for their critical review of this manuscript. Illustrations are by Eugene G. Leppanen and William L. Brudon.

### REFERENCES

1. Broadbent BH: A new x-ray technique and its application to orthodontia. *Angle Orthod* **1**: 45-66, 1931; reprinted in *Angle Orthod* **51**: 93-114, 1981.
2. Downs WB: Variation in facial relationships: their significance in treatment and prognosis. *AM J ORTHOD* **34**: 812-840, 1948.
3. Downs WB: The role of cephalometrics in orthodontic case analysis and diagnosis. *AM J ORTHOD* **38**: 162-182, 1952.
4. Downs WB: Analysis of the dento-facial profile. *Angle Orthod* **26**: 191-212, 1956.
5. Steiner CC: Cephalometrics for you and me. *AM J ORTHOD* **39**: 729-755, 1953.
6. Steiner CC: Cephalometrics in clinical practice. *Angle Orthod* **29**: 8-29, 1959.
7. Steiner CC: The use of cephalometrics as an aid to planning and assessing orthodontic treatment. *AM J ORTHOD* **46**: 721-735, 1960.
8. Tweed CH: Evolutionary trends in orthodontics, past, present, and future. *AM J ORTHOD* **39**: 81, 1953.
9. Tweed CH: The Fränkfort-mandibular incisor angle (FMIA) in orthodontic diagnosis, treatment planning and prognosis. *Angle Orthod* **24**: 121-169, 1954.
10. Ricketts RM: The influence of orthodontic treatment on facial growth and development. *Angle Orthod* **30**: 103-133, 1960.
11. Ricketts RM: Perspectives in the clinical application of cephalometrics. *Angle Orthod* **51**: 115-105, 1981.
12. Ricketts RM, Bench RW, Hilgers JJ, Schulhof R: An overview of computerized cephalometrics. *AM J ORTHOD* **61**: 1-28, 1972.
13. Jacobson A: The "Wits" appraisal of jaw disharmony. *AM J ORTHOD* **67**: 125-138, 1975.
14. Jacobson A: Application of the "Wits" appraisal. *AM J ORTHOD* **70**: 179-189, 1976.
15. Jarabak JR, Fizzell JA: *Technique and treatment with light-wire edgewise appliance*, ed. 2, St. Louis, 1972, The C. V. Mosby Company.
16. Coben SE: The integration of facial skeletal variants. *AM J ORTHOD* **41**: 407-434, 1955.
17. Wylie WL: The assessment of anteroposterior dysplasia. *Angle Orthod* **17**: 97-109, 1947.
18. Wylie WL, Johnson EL: Rapid evaluation of facial dysplasia in the vertical plane. *Angle Orthod* **22**: 165-181, 1952.
19. Sassouni V: A classification of skeletal facial types. *AM J ORTHOD* **55**: 109-123, 1969.
20. Sassouni V: The Class II syndrome: differential diagnosis and treatment. *Angle Orthod* **40**: 334-341, 1970.
21. Enlow DH, Moyers RE, Hunter WS, McNamara JA Jr: A procedure for the analysis of intrinsic facial form and growth. *AM J ORTHOD* **56**: 6-23, 1969.
22. Bimler HP: *The Bimler cephalometric analysis*, Wiesbaden, Germany, 1973.
23. Baumrind S, Frantz RC: The reliability of headfilm measurements. I. Landmark identification. *AM J ORTHOD* **60**: 111-127, 1971.
24. Harvold EP: *The activator in interceptive orthodontics*. St. Louis, 1974, The C. V. Mosby Company.
25. Woodside DG: *Cephalometric roentgenography*. In Clark J (editor): *Clinical dentistry*, Philadelphia, 1975, W. B. Saunders Company, vol. 2.
26. Broadbent BH Sr, Broadbent BH Jr, Golden WH: *Bolton standards of dentofacial developmental growth*. St. Louis, 1975, The C. V. Mosby Company.
27. Behrents RG, McNamara JA Jr: Cephalometric values derived from the Bolton standards. Unpublished data.

28. McNamara JA Jr, Ellis E, O'Connor KA, Howe RP: Cephalometric standards of adults with well-balanced faces. Unpublished data.
29. Bookstein FL: Foundations of morphometrics. *Ann Rev Ecol Syst* **13**: 451-470, 1982.
30. Bookstein FL: On the cephalometrics of skeletal change. *AM J ORTHOD* **82**: 177-198, 1982.
31. Bookstein FL: Measuring treatment effects on craniofacial growth. *In* McNamara JA Jr, Ribbens KA, Howe RP (editors): Clinical alteration of the growing face, Monograph 14, Craniofacial Growth Series, Ann Arbor, 1983, Center for Human Growth and Development, The University of Michigan.
32. Bookstein FL: The geometry of craniofacial growth invariants. *AM J ORTHOD* **83**: 221-234, 1983.
33. Bookstein FL: Modeling differences in cranial form. *In* Jungers WR (editor): Primate biology, New York, 1984, Plenum Press.
34. Scheideman GB, Bell WH, Legan HL, Finn RA, Reisch JS: Cephalometric analysis of dentofacial normals. *AM J ORTHOD* **78**: 404-420, 1980.
35. McNamara JA Jr: Components of Class II malocclusion in children 8-10 years of age. *Angle Orthod* **51**: 177-202, 1981.
36. Ellis E III, McNamara JA Jr: A cephalometric evaluation of maxillary incisor position. (Submitted for publication. )

*Reprint requests to:*

Dr. James A McNamara  
Center for Human Growth and Development  
The University of Michigan  
300 N. Ingalls St.  
Ann Arbor, MI 48109